

A PRICKY BUSSINESS : BILATERAL PNEUMOTHORAX POST ACUPUNCTURE



P.Thamotheran¹, V.H Ng¹, CS Lee¹, M Md Saed¹

1.Hospital Sultanah Aminah, Johor Bahru



1 INTRODUCTION

Acupuncture is a form of alternative traditional medicine used to treat various ailments. Complications of varying degrees have been reported, albeit less, largely due to lack of awareness. Pneumothorax happens when air trapped in the pleural cavity as a result of acupuncture needle penetration.

2 CASE REPORT

Mr C is a thin 71 year old gentleman, presented to emergency department (ED) with breathlessness after undergoing acupuncture due to palpitations for 2 months. He underwent a total of 8 sessions with 45 minutes each. Acupuncture needle was inserted at anterior and posterior chest wall. He experienced breathing difficulties with coughing soon after the treatment. Examinations revealed reduced air entry at bilateral lungs. Chest radiograph revealed bilateral pneumothorax but patient clinically stable without sign of tension pneumothorax. Vital signs and laboratory parameters were normal. Bilateral chest tubes were inserted at ED. Both tubes were removed at day 4 of admission with residual pneumothorax at right apex with minimal effusion. Patient was discharged well with follow up appointment.

3 DISCUSSION

Acupuncture is based upon 12 body meridians which corresponds to specific organ and as pathway for Qi (life force). Acupuncture effects on this force and produces desirable effects. A study of 229,230 patients during a 44-month period showed approximately 2.2% adverse events with only two pneumothorax cases reported^[1]. Patients who are thin have increased risk as their lungs located more superficially and have less adipose tissue^[2]. The common region of thorax associated are upper trapezius, paraspinal, medial scapular and subclavicular regions^[3]. Needle sizes range from 26 to 40 gauge and lengths from 0.5 inch to 2.5 inches^[4]. Stimulation of acupuncture sites to improve efficacy sometimes achieved with low intensity current^[5].

Acupuncture Needle Size Charts

Thickness (diameter)		Length	
Gauge	mm	Inches	mm
#42	0.14	0.50	12.00
#40	0.16	1.00	25.00
#38	0.18	1.50	38.00
#36	0.20	2.00	50.00
#34	0.22	2.50	63.00
#32	0.25	3.00	75.00
#30	0.30	4.00	100.00
#28	0.35	5.00	125.00
#26	0.40	6.00	150.00
#24	0.45		
#22	0.50		

Figure 1: Acupuncture needle length and diameter

4 CONCLUSION

Physician should be aware of pneumothorax as a complication of acupuncture. Knowledge of human anatomy, acupoints and patient's body habitus need to be addressed to prevent the complications.

5 REFERENCES

1. Hampton .D, Kaneko.R, Simeon.E(2014).Pneumothorax Med Acupunct. 1; 26(4): 241-245. doi: 10.1089/acu.2013.1022.
2. Chauffe.R, Duskin.A.(2006).Pneumothorax Secondary to Acupuncture Therapy.Southern Medical Journal • Volume 99, Number 11.
- 3.McCutcheon.L ,Yelland.M (2011).Iatrogenic pneumothorax: safety concerns when using acupuncture or dry needling in the thoracic region.Physical Therapy Reviews,Vol16 No.2.
- 4.Cai.C, Yang.W,Zhou.L(2011).Acupuncture in Treatment of Aging Spine-Related Pain Conditions,Pages 110-114.
5. Tony YC. Mark CL(2013) .Acupuncture.Mayo Foundation for Medical Education and Research n Mayo Clin Proc. 2013;88(10):1141-1146.

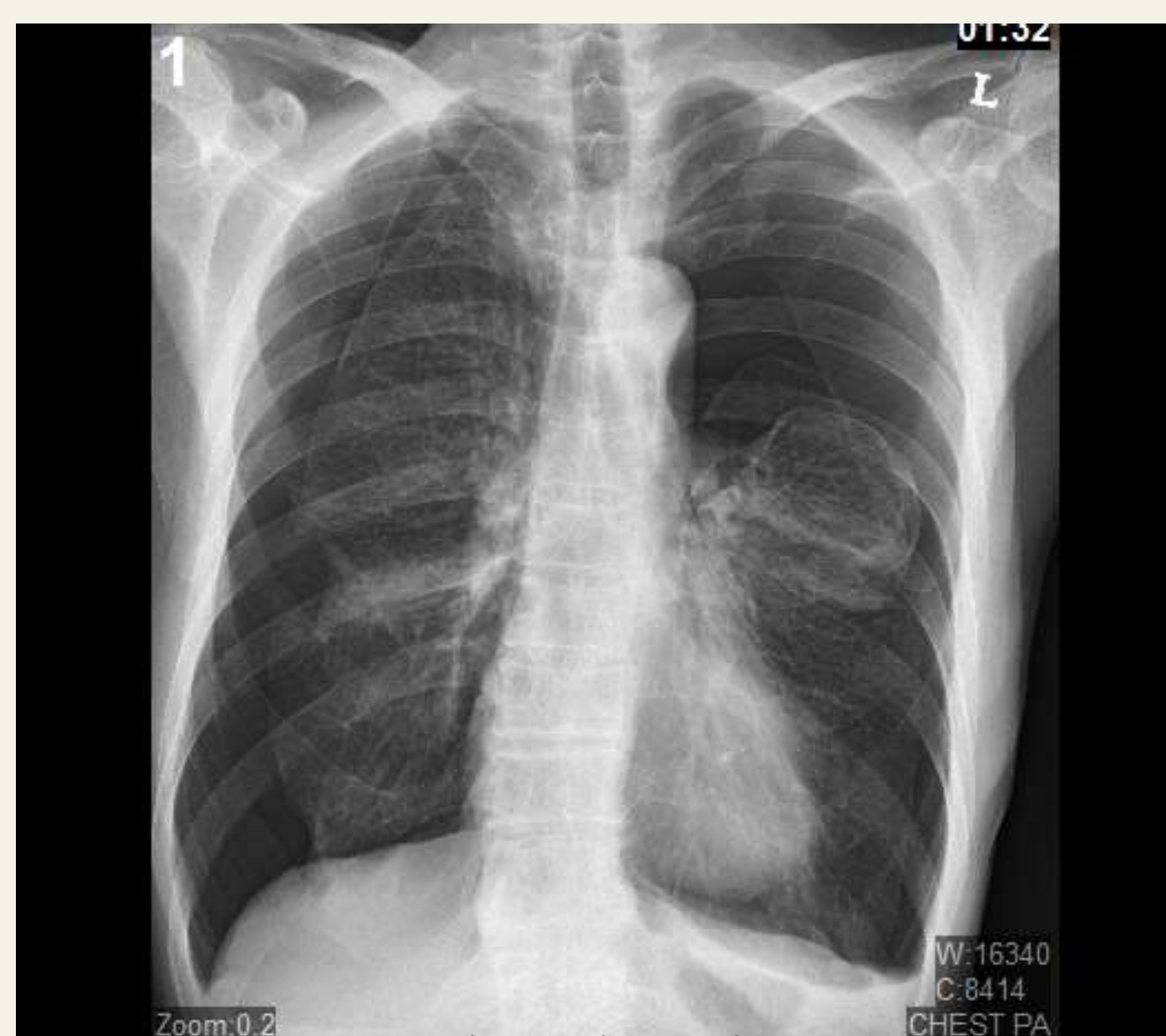


Figure 2: Chest Xray pre chest tube insertion

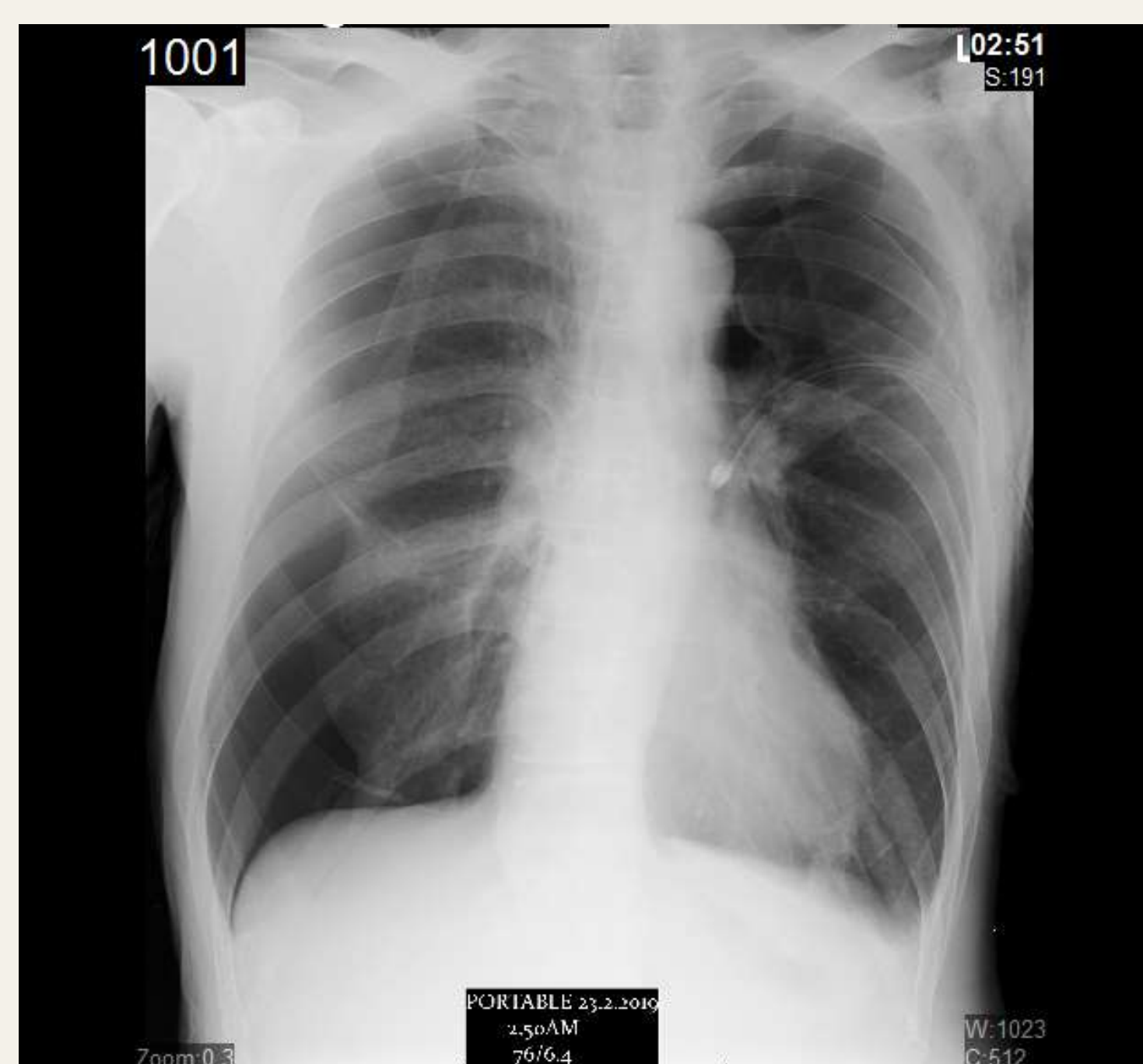


Figure 3: Chest Xray post left chest tube insertion