

EYE POPPING : TRAUMATIC GLOBE LUXATION: A CASE REPORT

Abdul Fattah bin Abdul Ghafar I Fathiyah Mazlan, Mohammad Al-Zakwan Mohamed Haidir, Arief Daniel Abdul Malik, Farah Alwi
iHospital Seri Manjung, Perak, Malaysia



Introduction

Globe luxation is one of the dreaded complication of blunt craniofacial trauma. It is often associated with high-energy trauma to the peri-orbital structures, typically involving significant craniofacial or maxillo-facial injuries; displacing the tissues within the orbit. We present a case of traumatic globe luxation following a road traffic accident, occurring without substantial maxillofacial bone injury, and highlights the patho-mechanism and importance of timely intervention.

Case Description

A 16-year-old male was involved in a road traffic accident between motorbike and lorry. He presented with pain and bleeding from his left eye. Initially, his Glasgow Coma Scale (GCS) was full, but he experienced a generalised tonic-clonic seizure during transfer. On arrival to the emergency department, his GCS had dropped to 8/15, necessitating intubation for cerebral protection.

Examination revealed his left eye protruding beyond the orbital rim, with the cornea facing downward and total hyphema present. There was no foreign body or active bleeding detected. The contralateral eye was normal, and the midfacial examination showed only a minimal laceration over the chin, with no significant swelling or crepitus. To protect the globe and preserve its integrity, a plastic cup with an eye patch was initiated by the prehospital team.

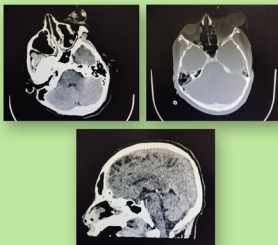
CT imaging of the orbit demonstrated inferolateral traumatic luxation of the left globe with optic nerve avulsion, vitreous haemorrhage, lens dislocation, and suspected tears in the extraocular muscles (medial and superior rectus). CT brain imaging revealed subtle acute punctate haemorrhages in the left frontal lobe and fractures involving the frontal bone, roof, and medial wall of the left orbit.

Despite the intact globe, the family declined the option of globe

repositioning to avoid secondary operation. Left globe enucleation, explorative conjunctival peritomy followed by transection of all rectus muscles and the optic nerve was performed.

Discussion

Globe luxation is a rare ophthalmic emergency where the globe protrudes anteriorly beyond the eyelid aperture, often associated with severe trauma. Mechanisms proposed include anterior luxation due to blunt forces, coup-contrecoup injury, reduced orbital volume from orbital roof fractures, sudden orbital shocks, violent beats, or a large foreign body acting between the eyeball and the orbit, and



the sudden reflex movement of the head in the opposite direction, which causes the eyeball to protrude toward the orbital position. According to the degree of eyeball luxation, it can be divided into semi-luxation and total luxation. Our patient had multiple orbital wall fractures and extraocular muscle injuries from a possible strong deceleration forces directed along the nasal aspect leading to a loss of orbital volume, anteroposterior traction onto the globe-nerve junction with added torsional tension contributing to the globe's luxation and separation of the optic nerve.

Early intervention was critical in preserving the globe's integrity to protect the protruded globe from contamination and further injury. While globe preservation is preferred for cosmetic and psychological reasons, globe enucleation particularly in involvement of optic nerve avulsion still considered as the best treatment option to prevent further infection and destruction to the surrounding structure. Globe enucleation was chosen in this case due to the severity of the optic nerve avulsion and the family's decision.

Conclusion

Traumatic globe luxation is an uncommon but critical condition, often associated with significant craniofacial injury. Mechanisms such as increase intraocular pressure, sudden extreme rotation of the globe, anterior globe luxation and retro-pulsion of the optic nerve have been described as the reason of this condition. Salvation of an intact globe starts from the pre-hospital care management of protecting the globe from further luxation and contamination; to early exploration in sterile condition for globe repositioning and preservation.

References :

1. Reyniers R, Paridaens D. Spontaneous globe luxation and floppy eyelid syndrome in a patient with Hashimoto's disease. Eye (Lond) 2007;21:303-4. [PubMed] [Google Scholar]
2. Morris W, Ossborn F, JC Flemming. Traumatic evulsion of the globe. Ophthal Plast Reconstr Surg. 2002;18:261-7
3. Gupta H, Natarajan S, Vaidya S, Gupta S, Shah D, Merchant R, et al. Traumatic eye ball luxation: A stepwise approach to globe salvage. Saudi J Ophthalmology. 2017;31:260-5
4. Em, K. K. J., Muhammed, J., Amin, N. H., & Jameelah, S. (2024). Traumatic globe Luxation and Optic Nerve avulsion: A case report and literature review. Cureus. <https://doi.org/10.7759/cureus.53150>