

"MYASTHENIA CRISIS IN PEDIATRIC – A CASE REPORT"

MUHAMMAD SUHAIMI O¹, ZH LOO¹, WENDY YR ONG¹, KHALID O¹
1. Emergency & Trauma Department, Hospital Sungai Buloh,
Selangor



1 INTRODUCTION

- Congenital myasthenic syndrome is defined as groups of conditions which muscle weakness that worsen with physical exertion, begins in early childhood. The severity of the disease varies greatly.
- Common clinical presentation include difficulty sucking on pacifier, inactivity, and decreased tone of the muscles.
- Respiratory muscles may be involved leading to respiratory failure requiring ventilator support
- Diagnosis should be suspected clinically, and confirmatory diagnostic testing be performed, including serum acetylcholine receptor antibodies, repetitive nerve stimulation, and electromyography.

2 CASE PRESENTATION

- 8-month-old girl, brought to emergency department for less responsive and bradypnea. According to mother, child appear to be less active from the night before and associated with poor feeding and episode of choking.
- There is no episode of fever, seizure or fall prior to presentation.
- Upon assessment, child is bradypnea, having generalized hypotonia and appear cyanosed. Child noted also to have bilateral eye ptosis.
- Blood gas shows uncompensated respiratory acidosis with high PCO₂ 96 and high lactate.
- Child was intubated in view of respiratory distress with premedication given IV Midazolam.
- Routine investigation sent is unremarkable. Chest X-ray done shows clear lung marking. RTK Covid-19 done is negative.
- Patient subsequently was admitted to ICU and further work out and shows AchR antibody is positive.

3 DISCUSSION

- Myasthenia Crisis remain one of true emergency presentation in emergency department.
- A high index of suspicion in emergency department for any patient came in with muscle weakness affecting mainly the ocular and respiratory depression is important.
- A trial of acetylcholinesterase inhibitor treatment is warranted for some but not all types of Congenital Myasthenia.
- Ventilation support remain one of important aspect of management in Myasthenia Crisis since hypoventilation can occur leading to respiratory failure.
- One of the things to consider in managing the airway is the use of neuromuscular blockade as the destruction of acetylcholine receptors creates succinylcholine resistance and increased sensitivity to nondepolarizing agents.

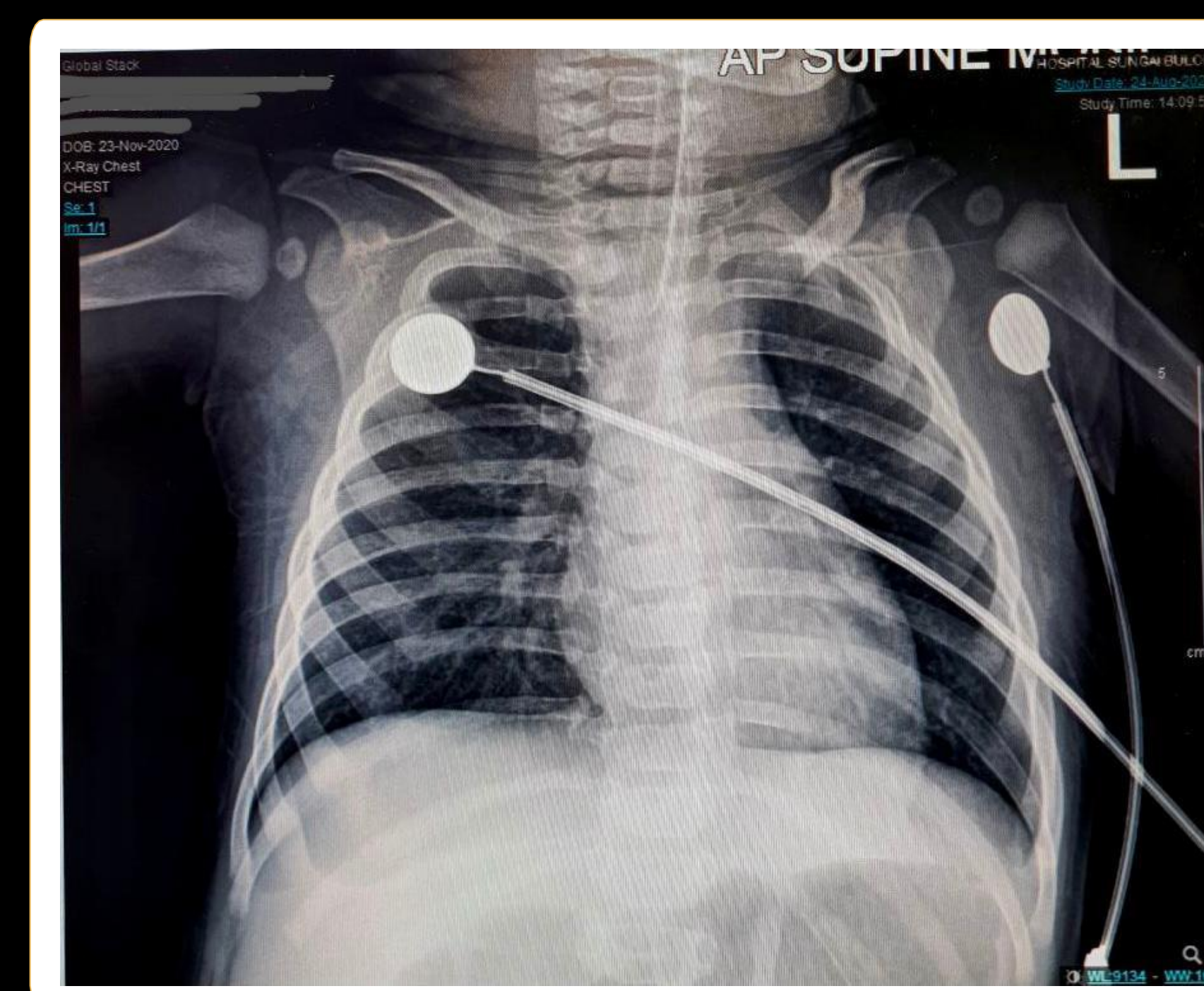


Figure 1

Figure 1 – Chest X-ray post intubation shows clear vascular marking

4 CONCLUSION

- Myasthenia gravis and myasthenic crisis are relatively rare disorders.
- Presentation can range from ocular through generalized to respiratory failure.
- This case highlights the importance of considering neuromuscular disorders in patients presenting with respiratory depression and ocular symptoms such as ptosis.

5 REFERENCES

- 1.O'Connell, K., Ramdas, S., & Palace, J. (2020). Management of Juvenile Myasthenia Gravis. *Frontiers in neurology*, 11, 743. <https://doi.org/10.3389/fneur.2020.00743>
- 2.Alam, M. S., & Devi Nivean, P. (2017). Early onset bilateral juvenile myasthenia gravis masquerading as simple congenital ptosis. *GMS ophthalmology cases*, 7, Doc07. <https://doi.org/10.3205/oc000058>
- 3.Peragallo JH. Pediatric Myasthenia Gravis. *Semin Pediatr Neurol*. 2017 May;24(2):116-121. doi: 10.1016/j.spen.2017.04.003. Epub 2017 Apr 7. PMID: 28941526.

6 ACKNOWLEDGEMENT

- No acknowledgement

7 DECLARATION OF CONFLICT FOR ALL AUTHOR

- No conflicts of interest