

FAT EMBOLISM SYNDROME

Ahmad Suhailan Bin Mohamed¹, Sherin Intan Binti Abu Bakar¹

¹Institut Jantung Negara (IJN), Kuala Lumpur, Malaysia

Details of corresponding authors:

Dr Ahmad Suhailan Bin Mohamed,

Pakar Perubatan Kecemasan (M.Med Emergency medicine),

Institut Jantung Negara (IJN), 145, Jalan Tun Razak, 50400 Kuala Lumpur

Tel: 60193362355

drsuhailan@gmail.com

CASE EXPLANATION:

29-year-old male was referred to the Emergency Department (ED) for suspected traumatic brain injury. He was involved in a motor vehicle accident (MVA) two days prior and sustained a close fracture of the right tibia and left radius. He started to have headache and vomiting a day after his MVA.

Patient was febrile, tachycardic, tachypneic and hypotensive. Petechial rash was visible around his neck and chest (Fig 1,2), and he had bilateral basal lung crepitations. High flow oxygen was administered with fluid resuscitation. Patient

had type I respiratory failure on arterial blood gas review. Bedside Focused Echocardiography and repeated FAST scans were unremarkable. Chest radiograph showed diffuse bilateral pulmonary infiltrates (Fig 4). CT brain showed no intracranial haemorrhage or focal brain lesion.

A diagnosis of Fat Embolism Syndrome (FES) was made. Patient was admitted to the Intensive Care Unit for supportive treatment and his right lower limb fracture was surgically fixed the next day. Patient made an uneventful recovery and was discharged a week later.

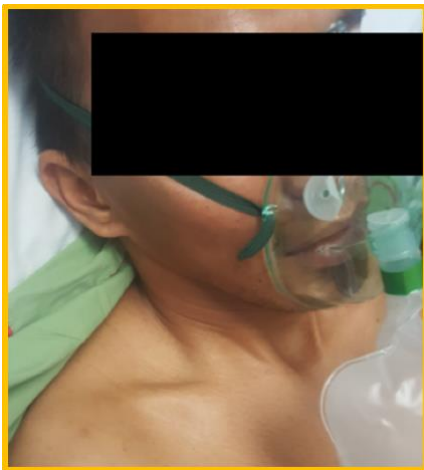

Figure 1

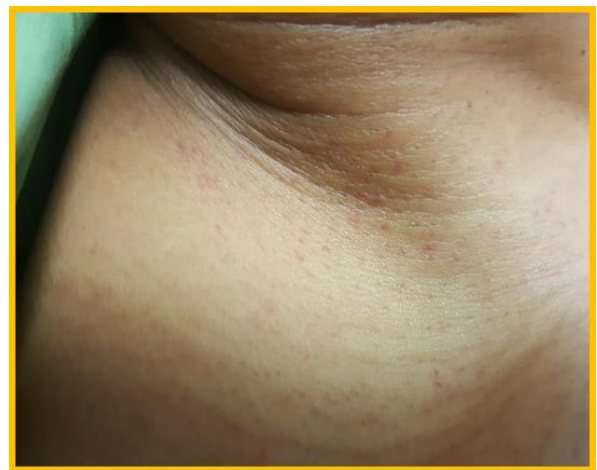

Figure 2

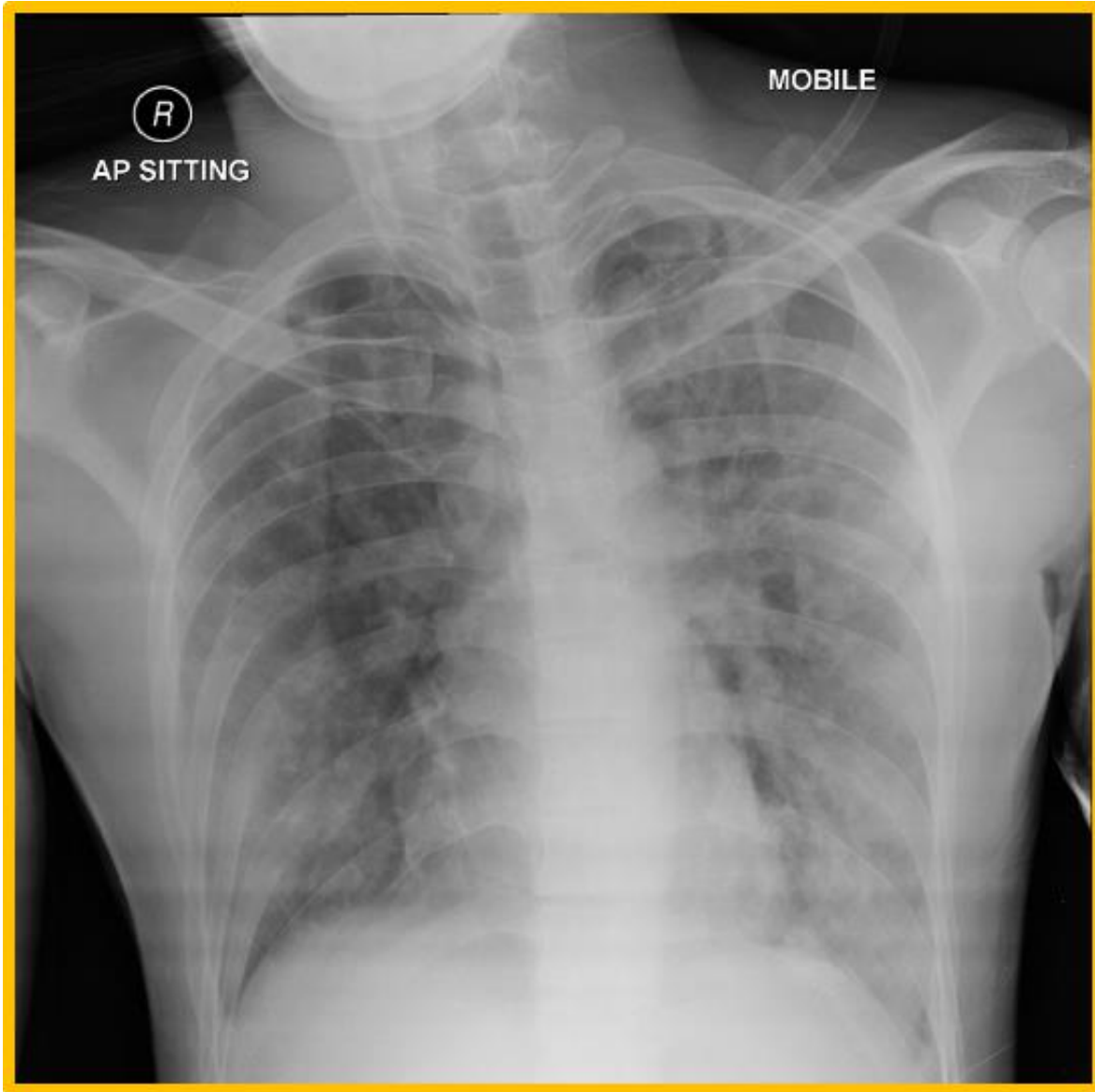


Figure 4: CXR

REFERENCES

- 1) Bulautan, SC. Rowe, VP. Fat Embolism. May 2017. Available from <http://emedicine.medscape.com/article/460524-overview>
- 2) Gupta A, Reilly CS; Fat Embolism, Continuing Education in Anaesthesia, Critical Care & Pain. 2007; 7 (5).
- 3) Nissar Shaikh. Early Management of Fat Embolism Syndrome. J Emerg Trauma Shock. 2009 Jan-Apr; 2(1): 29–33.
- 4) Weingart, S. Fat Embolism Syndrome. June 2014. Available from <https://lifeinthefastlane.com/ccp/fat-embolism-syndrome/>